

The Clinical Application of an Upper Limb Custom Silicone Interface: Observations of a Case Study

Robert J. Dodson, CPO, LPO, Bridget Jowid, OTR

ABSTRACT

Silicone interfaces have played an important role in the prosthetics field over the last three decades. From suspension techniques to the enhancement of comfort and protection of atypical or diseased residual limbs, silicone provides unique and valuable benefits that have helped countless individuals regain functionality. Beyond the world of prosthetics, silicone has become a mainstay in wound management, scar maturation, and in the overall promotion of healing during occupational and physical therapy. Practitioners now recognize that silicone interfaces can protect fragile skin in extreme cases such as severe burns and extensive skin grafts. Clinically, as we incorporate custom silicone into the mainstream design of the “standard” upper-limb prosthesis, we are beginning to see unexpected and exciting benefits. Although not formally studied, clinical observation has shown that people wearing an upper-limb prosthesis that incorporates a custom silicone interface gain greater range of motion at the elbow and wrist, report increased comfort and better tolerances of aggressive socket design, and experience greater protection of fragile skin. A recent case study within our clinical setting highlights the positive effects of a custom silicone interface on a chronic wound and provides real observation of the benefits that the addition of this material to the prosthetic design can have on this patient population. (*J Prosthet Orthot.* 2009;21:120–124.)

KEY INDEXING TERMS: upper extremity, amputation, silicone, custom interface, prosthetics, wound healing, occupational therapy

Silicone, a synthetic polymer made by repeating silicon to oxygen bonds to form polymeric chains, is a key component in a variety of medical applications.¹ In 1824, Jons Jacob Berzelius discovered silicon from the reduction of silicon tetrafluoride with potassium.¹ Silicon is the second most abundant element on earth, eclipsed only by oxygen, making up 25.7% of the earth’s crust. Frederick Kipping is credited as the father of silicone chemistry, because he was the first to develop a method to study organo-silicon compounds.² Between 1899 and 1937 he published 54 articles on the subject, but failed to see the potential commercial value of these new silicone compounds. In 1943, a new company by the name of Dow-Corning Corp. found an industrial use for silicone and began manufacturing silicone polymers.²

Silicone possesses unique properties such as hydrophobic qualities, a low surface tension, chemical stability, biocompatibility, and thermal stability.¹ By the end of the 1960s,

silicone materials were being used in orthopedic applications, catheters, drains/shunts, kidney dialysis, heart bypass machines, and aesthetic implants.¹ Recent developments in silicone technology are being used in rehabilitation in the form of scar management, wound care materials, burn management, and prosthetic interface materials.

THERAPEUTIC USES OF SILICONE

Clinicians use silicone products therapeutically because of their superior ability to treat and prevent hypertrophic and keloid scar formation.^{3,4} These abnormal types of scarring can significantly reduce range of motion, cause pain, and can limit a patient’s ability to perform activities of daily living. These scars can also pose psychological implications as a constant reminder of the trauma endured by the patient.³

Occupational therapists have evaluated studies on the therapeutic use of silicone for wound healing since the early 1980s. A thorough literature review in 1992 compiled and compared all of the studies relating to the effectiveness of silicone on the treatment of hypertrophic scar formation from the 1965 through the 1991 and discovered “significant trends” among the results.⁵ The author noted that “the application of silicone gel seems to normalize the texture, color, evaluation, and occurrence of subjective complaints (i.e., pain and pruritis) typically associated with hypertrophic scarring.”⁵ These findings were found to be “independent of the patient’s age, method of attachment of the gel, or the loca-

ROBERT DODSON, CPO, LPO, is affiliated with Advanced Arm Dynamics, Irving, Texas.

BRIDGET JOWID, OTR, is affiliated with Advanced Arm Dynamics, Irving, Texas.

Disclosure: The authors declare no conflict of interest.

Copyright © 2009 American Academy of Orthotists and Prosthetists.

Correspondence to: Robert Dodson, CPO, LPO, 3501 N. MacArthur Blvd., Suite 650, Irving, TX 75062; e-mail: rdodson@armdynamics.com

tion, age, or cause of the scar.”⁵ One of the articles reviewed indicated that silicone gel “had extensibility approximately equal to that of skin; therefore it is sufficient to cover joints.”⁶ Other key findings showed silicone is impermeable to bacteria (neither inhibits nor enhances bacteria growth), decreases pain during movement, increases mobilization, and decreases drying of the scar tissue.⁵ Clinical observations of four patients with open burn wounds who were treated with silicone gel therapy concluded that early reepithelialization occurred and no evidence of increased scarring was seen in these individuals during later assessments.⁷

In the early 1980s and through the 1990s, various types of silicone elastomer sheeting (Figure 1) began to be used on patients with hypertrophic scars.⁵ At this time, the precise mechanism of silicone elastomer sheeting has not been clearly defined; however, there is evidence that consistent use of this product can help minimize scar formation and increase scar elasticity. Thus, this product is widely accepted by wound care specialists and therapists.^{3,4}

The wound care and burn management field has also seen the emergence of silicone materials in clinical practice. Prevention of infection and quick closure of the wound is a primary concern.⁸ For example, products such as Biobrane dressing act as a semi-permeable pseudoepithelium, allowing gas exchange at the wound surface. The dressing reduces evaporative water loss from the wound by 90%, and because of adherence to the wound surface, Biobrane reduces pain and minimizes bacteria proliferation.⁹ A recent case study found silicone gel dressing “to be an effective wound covering” for a 14-month-old African American child who received a total body 3% scald burn.⁷ Another case study indicated perforated silicone sheeting assists in wound healing after a lower-limb amputation. This study observed that the “elastic properties of the silicone perforated sheeting provided an effective pressure dressing without causing further trauma or pain over the amputation stump.”¹⁰

PROSTHETIC USES OF SILICONE

Silicone was originally debuted in the prosthetics arena with the advent of the aesthetic hand prosthesis in the mid 1950s.¹¹ These passive devices restored near-normal appearance and improved patients’ overall function.¹¹ In 1986, Ossur Kristinsson introduced the first “silicone liner socket” in the form of the

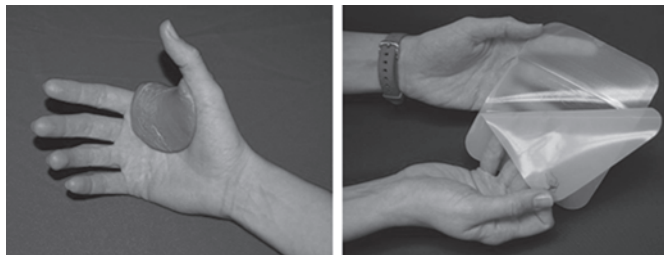

Figure 1. Examples of elastomeric sheeting for the management of scar tissue formation.

Icelandic Roll-On Silicone Socket. Over the past 2 decades, this concept and technology has revolutionized the fitting of lower-limb prosthetic devices. Suspension and comfort were the main objectives when using this type of silicone application, and great success has been achieved by both clinicians and patients alike.¹² More recently, the employment of vacuum assistance with silicone liner technology has been shown to create a negative pressure environment against the residual limb, thus eliminating much of the pistoning of the socket during the swing phase. Sealing type socket designs combine the flexible properties of silicone with the addition of a one-way valve to provide another option in the fitting of prosthetic devices.¹³

The emergence of the upper-limb specialist in the field of prosthetics over the last 10 years has led to a new focus on socket design and usage of flexible interface materials.¹⁴ As a result, clinical applications of silicone materials and their benefit in upper-limb prosthetic design are now being realized. More than 68% of upper-limb amputations occur in a traumatic scenario, increasing the likelihood of severe residual limb scarring.¹⁵ This fact makes it even more critical to use materials that minimize severe scar formation and assist in the management of scar formation (Figure 2). Working in conjunction with occupational therapists uniquely interested in upper-limb prosthetics, the advantages of applying silicone in scar, burn and wound management are now being correlated with benefits seen when silicone is introduced into prosthetic design.

Uellendahl et al.¹⁶ described the use of custom silicone sockets for myoelectric prostheses. This research concluded that custom silicone socket design enhanced three of the primary goals in fitting upper limb prostheses—comfort, function, and appearance.¹⁶ Along with these enhancements, custom silicone sockets are now being seen as a way to promote skin health, provide a proper wound healing environment, and possibly reduce the negative effects of hypertrophic and keloid scar formation found in patients with skin grafts and burns.

Silicone applications can also help those without major scarring or chronic wounds. Clinical observations of patients fit with custom silicone interfaces show improved range of motion at the elbow and wrist, greater overall comfort (especially for individuals with prominent bony anatomy), added protection to hypersensitive residual limbs, and improved

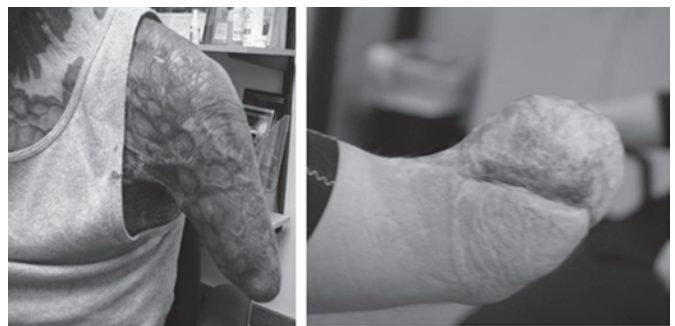

Figure 2. Examples of the severe scarring that can occur with extensive thermal injuries or skin grafting.

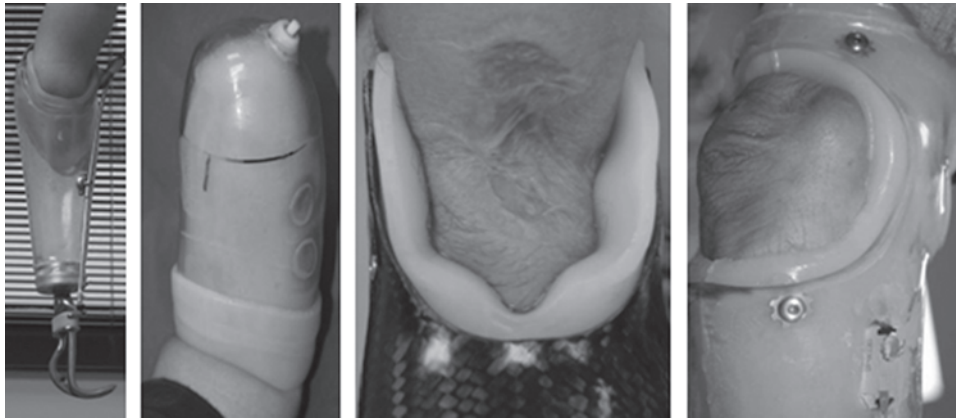


Figure 3. Four different examples of custom silicone interfaces incorporated into the prosthetic design. From the fitting of very short residual limbs, incorporation of negative vacuum, an increase in the tolerance of aggressive socket design, and the fitting of prominent bony anatomy, custom silicone allows for a multitude of options and creativity in the design of the upper-limb prosthesis.

weight-bearing properties within the prosthetic socket (Figure 3).

Custom silicone allows more aggressive inner socket modification and surmounts previous problems with placing rigid materials against the residual limb. Clinicians now are able to fit a greater range of anatomically contoured socket designs. Vacuum assistance in the form of negative vacuum and elevated vacuum is now being implemented into many prosthetic designs. The sealing properties of silicone provide better suspension and the potential to decrease proximal trimlines.¹⁷

SILICONE CASE STUDY

Clinical observations are an important first step in the research process and can help answer basic questions of efficacy and necessity. The following case study examines the therapeutic benefits of silicone in wound care and scar management as well as socket design, improved suspension, increased comfort, and improved range of motion for function.

The Subject, a 43-year-old white man, suffered third-degree electrical burns to more than 85% of his total body surface area. This traumatic work injury in 1999 resulted in bilateral transradial amputations, as well as severe scarring to his face, neck, chest, back, arms, and legs. The Subject fights recurring methicillin-resistant *Staphylococcus aureus* infections, primarily on his face. He has taken a proactive role in his health care, taking vitamins regularly and eating two healthy home cooked meals daily. Over the past 9 years, The Subject has worked with three different prosthetic companies and multiple occupational therapists to regain physical function. His initial bilateral, transradial, and myoelectric prostheses were fabricated using inner flexible liners made of Proflex™ with silicone. Although The Subject was highly motivated to wear his prostheses, his skin's sensitivity and lack of integrity made it difficult to wear the devices more than 2 or 3 hrs on a single day. A chronic wound developed on his left elbow soon after his initial fitting. The Subject reports, "Whenever my left side would get pressure and




Figure 4. Custom silicone interface along with the patient's residual limb model.

moisture, a sore would develop . . . My wounds would bleed daily. I had to change my sheets on a daily basis."

In June of 2007, The Subject's current prosthetist refabricated the inner flexible liners for both prostheses using Dragon Skin® Q - Shore 10A hardness platinum cure silicone rubber material from Smooth-On, Inc. The result was a custom silicone interface that represented The Subject's residual limb shape and contouring (Figure 4).

The new custom interfaces were approximately ¼ inch in overall thickness and were attached to an outer Durr-Plex™ frame using plastic rivets. Within a month of using this new liner on a daily basis, The Subject's wound began to heal. He reported that both of the prostheses were comfortable and that he was able to wear them all day (approximately 14 to 16 hrs daily). For 9 months, The Subject's wound healing progress was monitored; by the end of this period his red weeping wound was replaced with dry epithelial tissue, and this healed scar tissue appeared to be more supple (Figure 5). To date, no further wounds have developed in the areas that were previously problematic. An important aspect of this case is that there were no attempts made during this 9-month

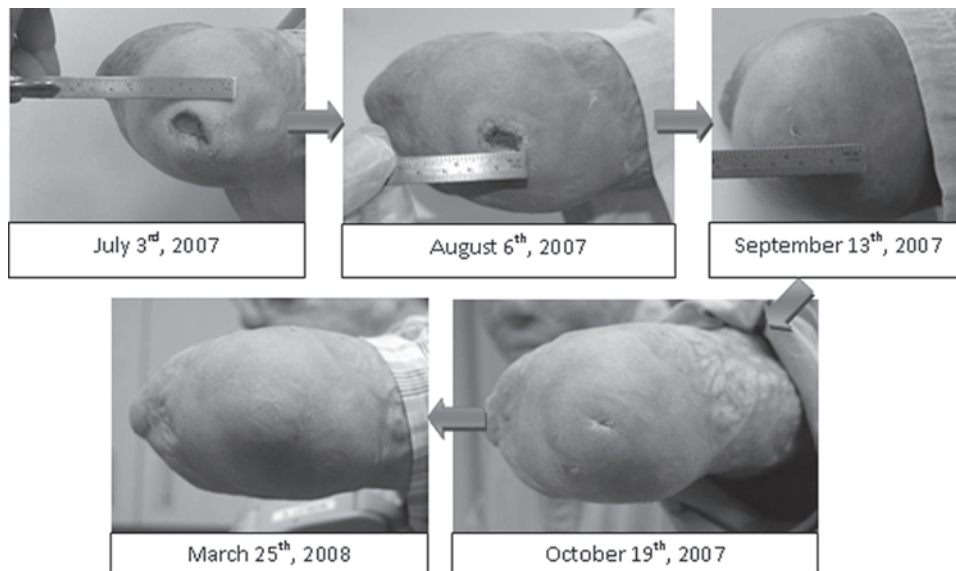


Figure 5. The Subject's wound healing progression over a ten-month period.

period at more traditional techniques to stimulate wound healing on The Subject's wound such as electrical stimulation or ultrasound.

DISCUSSION

This dramatic case study demonstrates the need for further research on the implications and benefits of silicone use with amputees and specifically those with open wounds or scarring. These clinical observations raise the question of how and why a chronic wound healed inside a prosthesis. The hypothesized reasoning is that the silicone provided a wound-healing environment, i.e., one free from infection, protecting the wound from negative factors such as friction or tension on suture lines, and providing the appropriate moisture wounds need to promote healing.^{3,18,19}

This case study also demonstrates the importance a patient with bilateral amputations will place on the ability to wear his or her prostheses. Normal protocol with any patient presenting with an open, weeping wound would dictate that the patient be strongly advised to discontinue the use of his or her prosthesis and wait until the wound is completely healed before continuing with prosthetic rehabilitation. Very few patients who present with bilateral amputations, however, will accept this solution when they have no sound side hand on which to depend. In The Subject's case, we were forced to consider other alternatives to the cessation of using his left prosthesis until his chronic wound healed completely. A custom silicone interface provided the suitable, "cushioned" material he needed to continue wearing his left prosthesis. What we did not foresee was that this silicone interface would not only create an environment that protected the patient's current wound from worsening, but would also help to heal this same wound in a relatively short timeframe.

When The Subject began wearing his new custom silicone interface, his wound was considered to be a red, chronic, not

yet infected wound in the inflammatory phase of the healing process. At that time he was only wearing his prosthesis 2 to 3 hrs a day. One year later, he is now able to wear his prostheses for periods up to 16 hrs a day. His chronic wound is completely healed and presents with aged scar tissue that is more pliable and able to withstand normal shear and pressure forces. Furthermore, because of the improved comfort and protection of the residual limb, he had overall improved function in his daily activities, improved range of motion at his elbows, and has avoided reinjuring his residual limbs even though his overall length of wear time and heavy duty activity level have increased dramatically.

Many questions arise from the clinical observations with this specific case study that deserve mention. First of all, why did this particular wound heal initially and stay healed long term? And what properties exist that allow a chronic wound to heal completely within the confines of a prosthetic socket? What types of pressure does a custom silicone interface exert on a residual limb? And what type of humidity levels are present underneath a custom silicone interface and are these pressures and humidity levels appropriate for overall skin health? Many opportunities exist for further research on these topics. Once we address these core questions, we can then consider when and how to use custom silicone interface systems for the treatment, of wounds, hypertrophic areas, and keloid scars.

CONCLUSION

Silicone is a unique substance that has furthered our ability to treat many challenging cases within the prosthetic and therapeutic community. Although we are just beginning to understand the benefits this material offers upper-limb amputees, we do know that the introduction of the custom silicone interface into mainstream prosthetic design affords the clinician more options in the effort to successfully fit

upper-limb patients. There is ample room for further research as described earlier as well as further descriptions of unique applications of this material and its potential for this patient population.

ACKNOWLEDGMENTS

The authors thank Carolyn Skokan, RN, a retired wound care specialist for her advice and expertise. The authors are extremely grateful to Julie Lake for her editing and literary review.

REFERENCES

- Colas A, Curtis J. Silicone biomaterials: History and chemistry & medical applications of silicones. In: Ratner B, Hoffman A, Schoen F, et al., eds. *Biomaterials Science, Second Edition: An Introduction to Materials in Medicine*. San Diego, CA: Elsevier Academic Press; 2004:80–86.
- Plastics Historical Society. Available at: <http://www.plastiquarian.com/kiping.htm#top>.
- Berman B, Perez OA, Konda S, et al. A review of the biologic effects, clinical efficacy, and safety of silicone elastomer sheeting for hypertrophic and keloid scar treatment and management. *Dermatol Surg* 2007;33:1291–1303.
- de Linde L, Knothe B. Therapist's management of the burned hand. In Hunter JM, Mackin EJ, Callahan AL, et al., eds. *Rehabilitation of the Hand and Upper Extremity*. St. Louis: Mosby Inc.; 2002:1492–1526.
- Farquhar K. Silicone gel and hypertrophic scar formation: a literature review. *Can J Occup Ther* 1992;59:78–86.
- Quinn KJ, Evans JH, Courtney JM, et al. Non-pressure treatment of hypertrophic scars. *Burns* 1985;12:102–108.
- Quinn KJ. Silicone based scar therapy. *Care Sci Pract* 1986;4:7–9.
- Chavez B. Addressing the pain: making the case for using a silicone dressing in burn wound management. *Ostomy Wound Manage* 2004;50:11–12.
- Smith K, Price J. Care of the hand wound. In: Hunter JM, Mackin EJ, Callahan AL, et al., eds. *Rehabilitation of the Hand and Upper Extremity*. St. Louis: Mosby Inc.; 2002:331–343.
- Gleaves JR, Eldridge K. Addressing the pain: silicone sheeting as an alternative to elastic bandages in dressing lower extremity amputations. *Ostomy Wound Manage* 2004;50:8–10.
- Pillet J, Mackin E. Aesthetic hand prosthesis: Its psychological and functional potential. In: Hunter JM, Mackin EJ, Callahan AL, et al., eds. *Rehabilitation of the Hand and Upper Extremity*. St. Louis: Mosby Inc.; 2002:1461–1472.
- Baars EC, Geertzen JH. Literature review of the possible advantages of silicone liner socket use in trans-tibial prostheses. *Prosthet Orthot Int* 2005;29:27–37.
- Haberman L. Silicone-only suspension (SOS) with socket-loc and the ring for the lower limb. *J Prosthet Orthot* 1995;7:2.
- Lake C. The evolution of upper limb prosthetic socket design. *Journal of Prosthetics and Orthotics* 2008;20:85–92.
- Dillingham TR, Pezzin LE, MacKenzie EJ. Limb deficiency and amputation—epidemiology and recent trends in the US. *South Med J* 2002;95:875–883.
- Uellendahl J, Mandacina S, Ramdial S. Custom silicone sockets for myoelectric prostheses. *J Prosth Orthot* 2006;18:35–40.
- Miguel J, Conyers D, Lang M, et al. Transradial and wrist disarticulation socket considerations: case studies. *J Prosthet Orthot* 2008;20:118–125.
- Evens RB, McAuliffe JA. Wound classification and management. In: Hunter JM, Mackin EJ, Callahan AL, et al., eds. *Rehabilitation of the Hand and Upper Extremity*. St. Louis: Mosby Inc.; 2002:311–330.
- O'Donovan DA, Mehdi SY, Eadie PA. The role of mepitel silicone net dressings in the management of fingertip injuries in children. *J Hand Surg (Br)* 1999;6:727–730.

OPERF

The Orthotic and Prosthetic
Education and Research Foundation

The NEW Orthotic and Prosthetic Education and Research Foundation is working hard to benefit the entire field of Orthotics and Prosthetics.

- Raising funds to promote the O&P profession through education, research, the education of deserving individuals and to generally raise the standards of education and research in the profession.
- Promoting the profession through public education to enhance the public's knowledge of Orthotics and Prosthetics and to assist in building the capacity to educate and train future members of the profession.

Visit www.operf.org to learn more about what the OPERF is doing for the Orthotic & Prosthetic Profession.