AMERICAN ACADEMY OF ORTHOTISTS AND PROSTHETISTS
Professionals Advancing Care Through Knowledge
Journal of Prosthetics & Orthotics

The Transradial Anatomically Contoured (TRAC) Interface: Design Principles and Methodology

John M. Miguelez, CP, FAAOP
Christopher Lake, CPO, FAAOP
Dan Conyers, CPO
John Zenie, CPO, MBA

ABSTRACT

Although there are many variations of the self-suspending transradial (below elbow) level interface, they generally can be divided into two styles: the Muenster-type and Northwestern University Supracondylar Suspension Technique designs. Variations of these styles often represent practitioner interpretation and an evolutionary process to enhance comfort, stability, and suspension. The Transradial Anatomically Contoured (TRAC) interface incorporates design elements from both the Muenster and Northwestern interfaces with more aggressive contouring of the anatomy to maximize load tolerant areas of the residual limb, as demonstrated by the radiologic analysis in this text. In the medial/lateral plane, the interface focuses the compression anterior and slightly inferior to the epicondyles, specifically about the radial head on the lateral aspect. In addition, on the anterior/posterior plane, suspension is achieved by precisely directed compression into the cubital fold and supra-olecranon region. A critical element in the successful design of the Transradial Anatomically Contoured interface is extensive anatomic contouring of the antecubital region. The combined effects of medial/lateral and anterior/posterior compression along with contouring of the musculoskeletal structure of the residuum allow enhanced comfort, suspension, and stability throughout an increased range of motion.

The introduction of the self-suspending interface for the transradial level amputee dramatically improved patient comfort and acceptance. Many body-powered prosthetic users have benefited from the enhanced comfort of self-suspended sockets that, by design, require a less restrictive control harness. Self-suspending interfaces also fueled the evolution of myoelectric prostheses because no external suspensory component was necessary, thus eliminating the need for a harness.[1] It is likely that the advancements and acceptance of myoelectrically controlled prostheses would not have been possible without the self-suspending transradial interface.

The self-suspending transradial level interface design has dramatically evolved since the introduction of the Muenster-type socket in the 1960s. The Muenster-type design achieves suspension primarily through anterior/posterior (A/P) compression with some degree of medial/lateral (M/L) stabilization. This socket technique has been taught throughout the world and has led to additional innovations. Perhaps the most notable is the Northwestern University Supracondylar Suspension Technique. Unlike its predecessor, the Northwestern design relies primarily on compression in the M/L plane superior to the epicondyles with less restrictive A/P trim lines.[1]

Although there are significant advantages to both of these self-suspending designs, patients who have worn them often have certain limitations. Impingement of the skeletal substructure by the interface in the epicondylar region limits range of motion. High, inflexible trim lines about the A/P aspect also restrict the range of motion and can be problematic in donning and doffing the prosthesis. Conversely, a reduction of A/P compression can lead to loss of suspension and stability, loss of skin-to-electrode contact, or excessive force to the cut end of the bone.

The Transradial Anatomically Contoured (TRAC) interface, used clinically by the primary author since the late 1980s, incorporates design elements from both the Muenster and Northwestern interfaces with more aggressive contouring of the anatomy to maximize load-tolerant areas of the residual limb. Similar to the Muenster-type interface, the TRAC retains the high olecranon encapsulating posterior trim line and the anterior trim line extending to the cubital fold with a channel that allows relief for the biceps tendon.[2,3] Although the Muenster socket suspension relies primarily on A/P compression, and the Northwestern socket uses M/L, the TRAC uses both A/P and M/L compression augmented by contouring of the musculoskeletal presentation distal to the cubital fold for enhanced comfort and stability.

The TRAC addresses the deficits of previous designs by contouring five key areas: 1) the antecubital region, 2) the olecranon region, 3) the epicondylar region, 4) the distal radial region, and 5) the wrist extensor and flexor musculature. With the compression and contouring of the soft tissue of the antecubital region, A/P stability is achieved while enhancing the suspension characteristics of the interface. Similarly, compression and contouring in the olecranon region promotes A/P stability while opposing the forces applied in the antecubital region to augment suspension and range of motion. Compressing the soft tissue anterior and slightly inferior to the epicondyles creates efficient stability and suspension of the interface throughout the elbow's range of motion. The TRAC interface also transfers the load from the distal end of the radius to the more load-tolerant musculature about the medial and lateral aspects of the radius and ulna.

Volume containment and M/L stability are achieved by compression of the soft tissue inferior and superior to the wrist flexors and extensors, creating a compartment for the muscles to contract without restriction, in contrast to other designs that compress all tissue in the M/L plane to achieve stability, often resulting in atrophy. This alignment, along the longitudinal axis of the muscle belly, promotes more efficient and consistent contractile activity.

Radiologic and range of motion analyses of all three interface designs were conducted by fabricating diagnostic interfaces representing each design for a 42-year-old man with a mid-length transradial traumatic amputation. The guidelines specified by Hepp and Kuhn4 were used for the Muenster-type socket, and Billock's1 guidelines were used for the Northwestern University Supracondylar Socket. Using a Swissray-Swissvision 7.2.2.2, radiographs were taken by an independent imaging facility of the patient wearing each diagnostic interface (Swissray, Hochdorf, Switzerland). The patient's elbow was positioned at approximately 90╟ degrees, and radiographs were taken with each interface in the sagittal plane: one unweighted and one with a five-pound weight secured to the distal aspect of the diagnostic interface (Figure 1) . A five- pound weight was chosen to simulate a typical lever arm load of a definitive prosthesis. An appreciable A/P displacement of the radius and ulna was noted in the Muenster (Figure 2) and Northwestern (Figure 3) design interfaces. This displacement was not apparent in the weighted condition of the TRAC (Figure 4) . Of additional importance, the radiograph of the nonweighted TRAC showed a more stable radial and ulnar angle in relationship to the posterior plane of the interface.

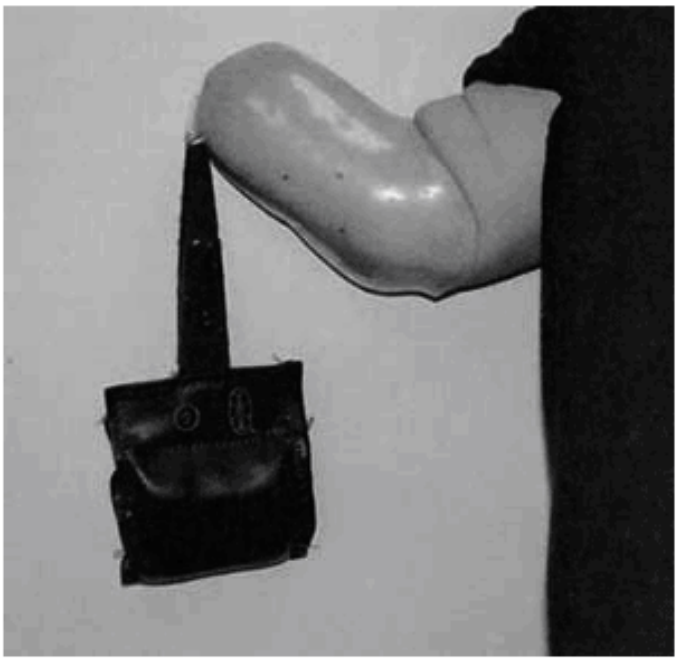

Figure 1. Interface in weighted condition.

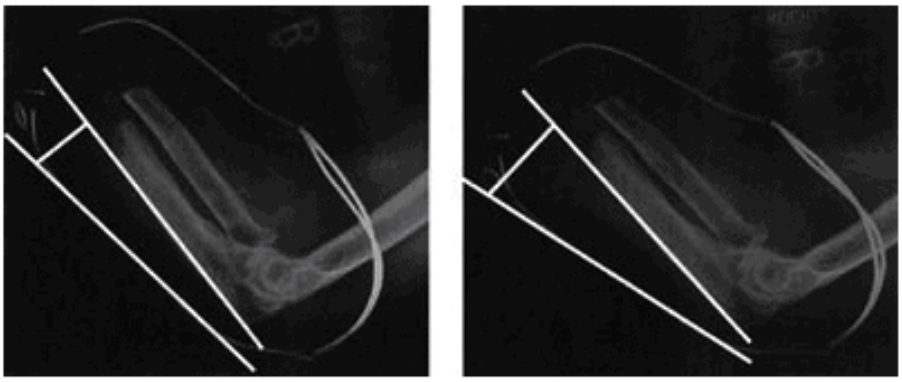

Figure 2. Muenster radiologic analysis (no load on left, with load on the right).

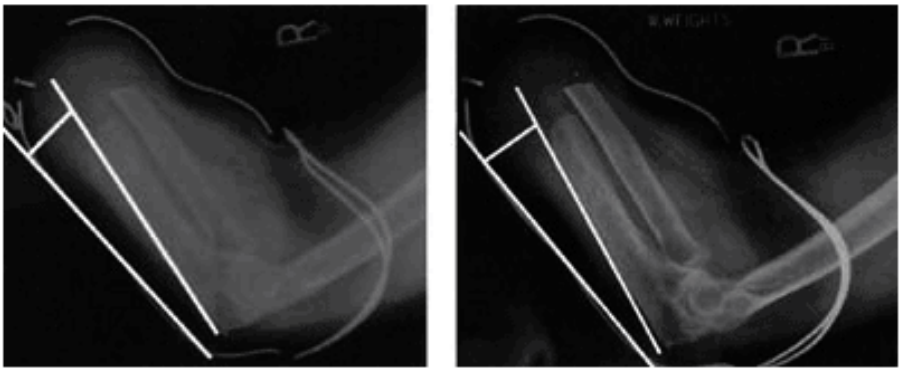

Figure 4. TRAC radiologic analysis (no load on left, with load on the right).

The analysis of the radiologic examination clearly demonstrates that the position and degree of displacement of the skeletal substructure while wearing the TRAC interface are less affected during loading than are those factors during wear of the other two interface designs (Table 1) . These findings are consistent with the authors' clinical experience during the last 14 years and are due, in part, to the use of hydrostatic pressure complimented by muscle contouring distal to the cubital fold in the TRAC interface, whereas the other two interfaces rely primarily on hydrostatic pressure and soft tissue compression. The analysis of range of motion was conducted by marking a line bisecting the lateral aspect of each interface design and marking a line on the patient's upper arm parallel with the humerus (Figure 5) . With the use of a goniometer, angle measurements were taken of the patient's maximum elbow flexion and extension without an interface and during wear of each interface design. The results of the range-of-motion analysis, found in (Table 2) , indicate that the TRAC allowed the most extensive range of flexion and extension of the three self-suspending interface designs.



Table 1. Radiologic angles

Socket Condition	No Load	With Load	Angle Difference
Muenster	10°	15°	+5°
Northwestern	10°	15°	+5°
TRAC	8°	8°	0°

Table 1. Radiologic angles

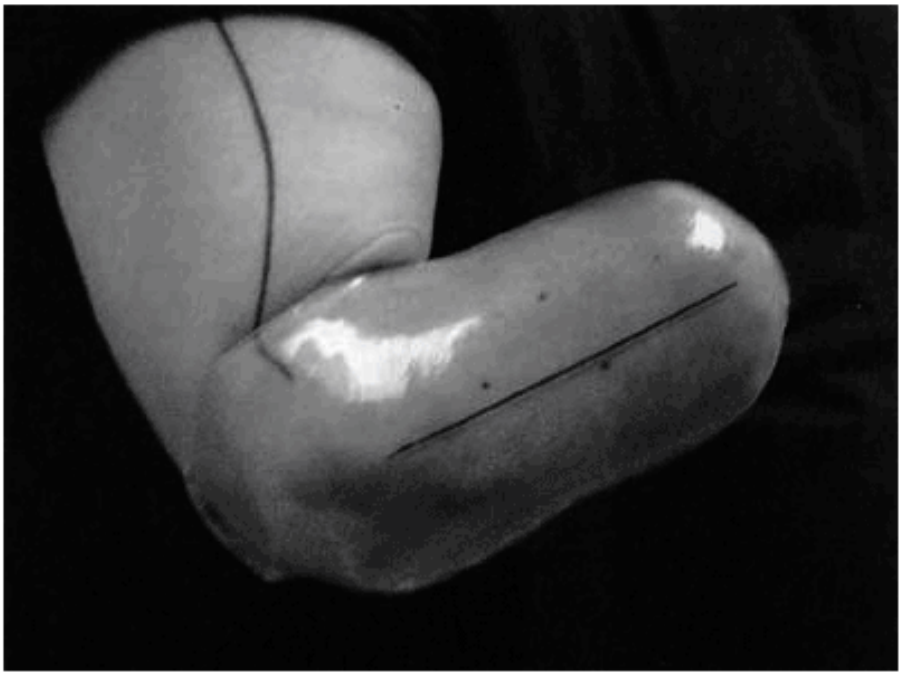

Figure 5. Preparation for range of motion analysis (Muenster design).

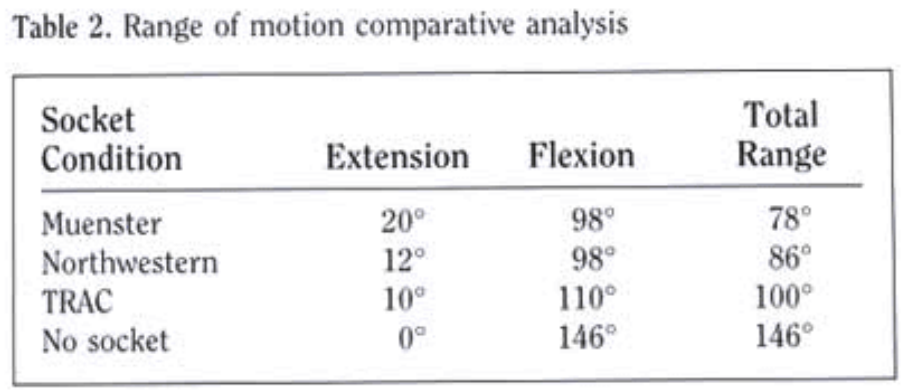

Table 2. Range of motion comparative analysis

Socket Condition	Extension	Flexion	Total Range
Muenster	20°	98°	78°
Northwestern	12°	98°	86°
TRAC	10°	110°	100°
No socket	0°	146°	146°

Table 2. Range of motion comparative analysis

METHODS

IMPRESSION TECHNIQUE

The impression technique begins with a careful analysis of the patient's residual limb, noting the range of motion, sensitive areas, scar/graft tissue integrity, and musculature. With the patient's elbow at 90╟, palpate the patient's cubital fold area to determine the appropriate depth of the antecubital channel (AC) and the amount of compression that can be applied to the supra-olecranon region. This can best be accomplished by securing the biceps tendon in the cubital fold area between the index and middle fingers while directing pressure to an area approximately one to two centimeters proximal to the olecranon process (Figure 6) . Next, palpate the area anterior and slightly inferior to the epicondyles using the thumb and index finger, approaching from the anterior or posterior aspect (Figure 6) . The authors prefer to approach from the posterior aspect of the elbow compartment because one can get a more distinct and exact definition of the skeletal substructure. However, this can be challenging for larger residual limbs or clinicians with smaller hands.

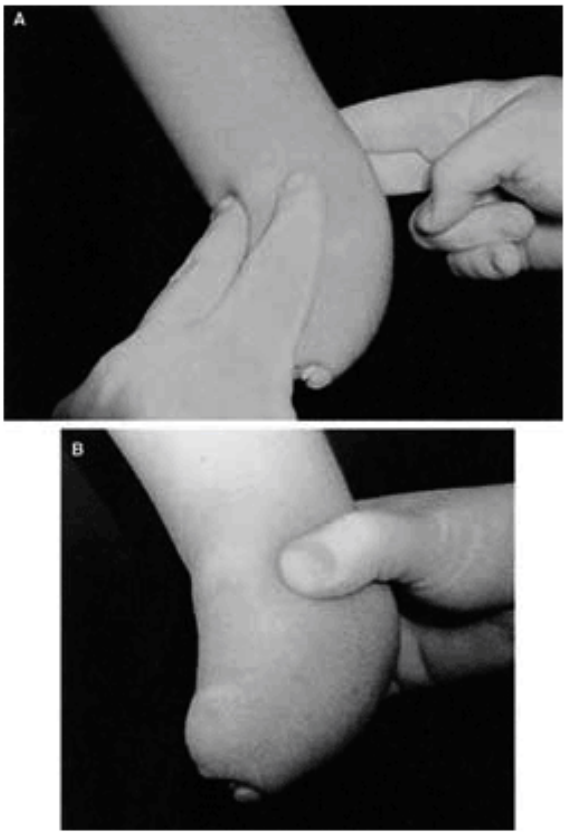

Figure 6. (A) Delineation and identification of biceps tendon. (B) Delineation and identification of epicondylar region.

From the lateral aspect, one should be able to palpate the head of the radius while exerting pressure toward the olecranon process. Medially, the area is less distinct and requires alignment with the lateral finger placement to provide a symmetrical compression. It is important to do this before the impression process to ensure that both the clinician and the patient are aware of the correct finger placement. This ensures the patient will be able to guide finger placement during the impression process because it is difficult to palpate the bony substructure through the plaster wrap. It is important to note any changes in the anatomy before one begins the impression technique. Because a large percentage of individuals who have transradial limb deficiency have experienced amputation secondary to trauma, the anatomy often is displaced. Specifically, genetic differences can affect the prominence and location of the epicondyles, the prominence of the olecranon process, the presence of the radial head, and the location and development of the biceps tendon.

At this point, stage the impression material using the following method.

- Prepare two (4-inch wide) extra-fast-setting plaster splints 10 layers thick that will form the medial and lateral stabilizers. Splint length is approximately 3 to 5 cm larger than the medial and lateral aspect of the residual limb, respectively.
- Prepare one to two rolls of 4-inch elastic plaster wrap, depending on the size of the residual limb.
- Prepare one to two rolls of 4-inch rigid extra-fast-setting plaster wrap, depending on the size of the residual limb.

(Note: it is important to stage plaster splints before preparing the residual limb for impression because the marks that will be applied to the stockinette can reposition with residual movement. An expeditious impression ensures accurate transfer of the markings.)

First, apply a liberal amount of petroleum jelly or a similar separating substance to the residual limb to ensure ease of impression removal. Place a tightly fitting, wet, thin stockinette over the residual limb to obtain good soft tissue compression and a barrier. A typical ("Figure 8") elastic strap is attached to the stockinette to ensure consistent tension throughout the impression technique. With the patient's elbow in a 90╟ position, mark the following surface anatomy with an indelible pencil:

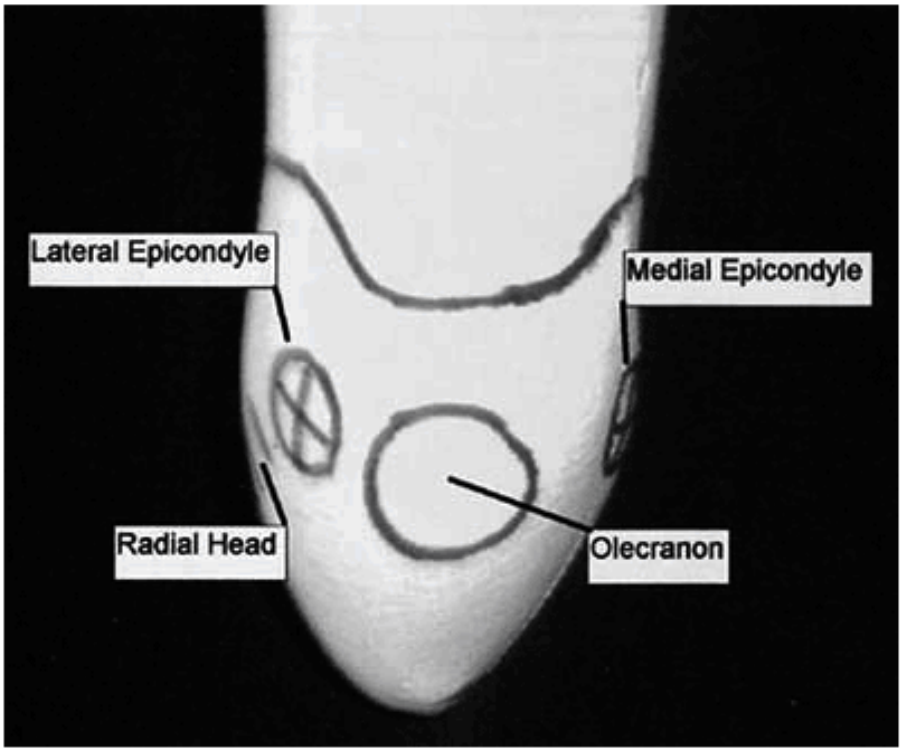

Figure 8. Delineation of posterior trim line.

- Medial and lateral epicondyles;
- Borders of the olecranon
- Distal cut end of the radius and ulna
- Scar or graft tissue and sensitive or painful areas; and
- Biceps tendon.

Establish the preliminary trim lines for the interface.

- The anterior trim line follows the cubital fold. The medial and lateral borders should parallel the medial border of the ulna and the lateral border of the radius (Figure 7)

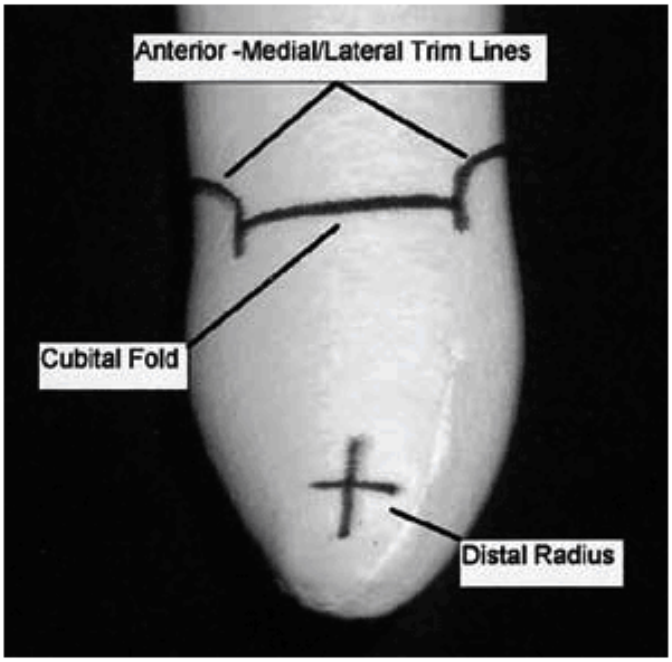

Figure 7. Delineation of anterior trim line.

- The posterior trim line is approximately 12 to 18 mm proximal to the superior aspect of the olecranon, with a width similar to the width of the olecranon (Figure 8) . Mark the apex of the medial and lateral trim lines approximately 40 to 50 mm proximal to the superior aspect of the epicondyles. A radius can then be established for the medial trim line from the medial border of the anterior trim line through the previously marked apex, extending to the medial border of the posterior trim line (Figure 9) . The lateral trim line can be established in a similar manner.

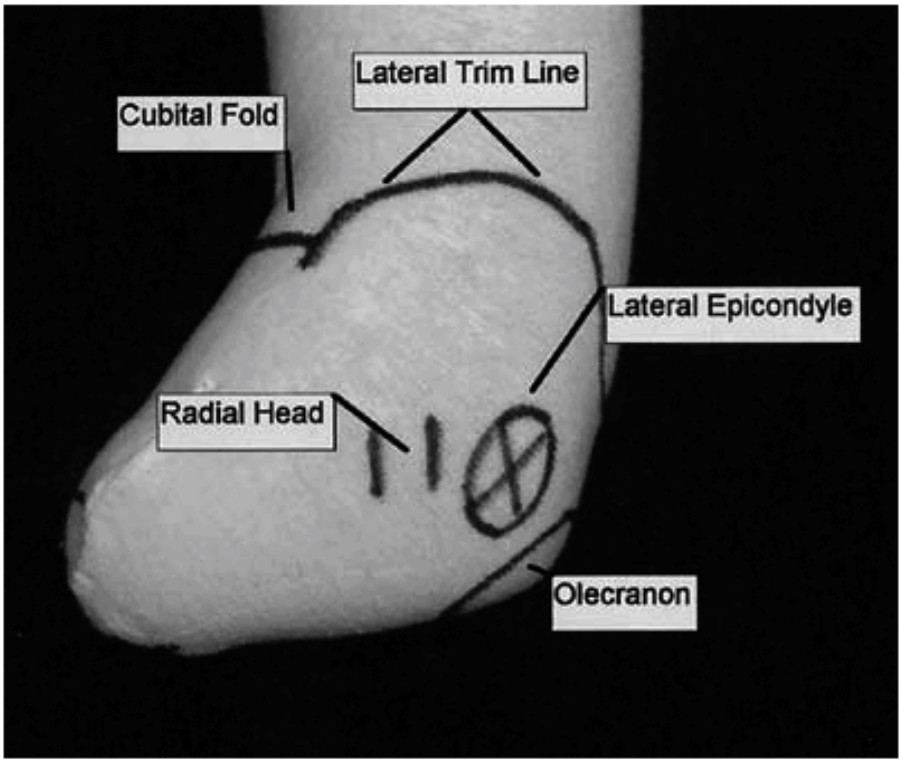

Figure 9. Delineation of lateral trim line.

Wrap the elastic plaster bandage over the distal aspect of the residuum, extending one centimeter proximal to the cubital fold and the previously delineated anterior trim line while not exceeding the pre-established posterior trim line. (Should the plaster wrap extend past the posterior trim line, removal of the plaster impression will be difficult.) With two layers of the elastic plaster bandage applied, place the medial and lateral splints, ensuring that they extend just past the margins of the trim lines, and secure them with the remaining elastic plaster bandage. (Note that when the index finger and thumb are applied to the area anterior and slightly inferior to the epicondyles, the compression will result in distraction of the plaster wrap. Ensuring that the medial and lateral plaster splints extend sufficiently past the trim lines will compensate for plaster distraction.)

The technique is completed by applying two to four layers of rigid fast-setting plaster bandage. Verify the patient's elbow is positioned at 90╟, and place the tips of the thumb and index finger in the area anterior and inferior to the epicondyles as previously described, applying force toward the olecranon process. Often the web space of the same hand can be used to stabilize the plaster superior to the olecranon process to ensure appropriate contouring of the supra-olecranon region. Once this has been established, compress the borders of the biceps tendon with a force directed to the olecranon process, using the index and middle finger of your remaining hand. This compression will establish the depth of the AC. Finger compression is maintained until the plaster has set.

The negative model is removed in the following manner. Trim the stockinette anteriorly and posteriorly to the margin of the plaster impression and remove the (Figure 8) harness. Range the residual limb passively without distorting the impression, while ensuring the patient remains relaxed. Removal of the negative impression is much more difficult if the patient is contracting the musculature of the residuum. Gently glide the olecranon out of the impression, followed by the rest of the residual limb. It may be necessary to coax the proximal soft tissues before doffing the negative mold.

MODEL RECTIFICATION

Once the negative mold has been filled with number 1 molding plaster and a pipe mandrel, carefully remove the negative mold, revealing the positive model. Re-establish trim lines, bony prominences, and any additional areas marked earlier (Figure 10) .

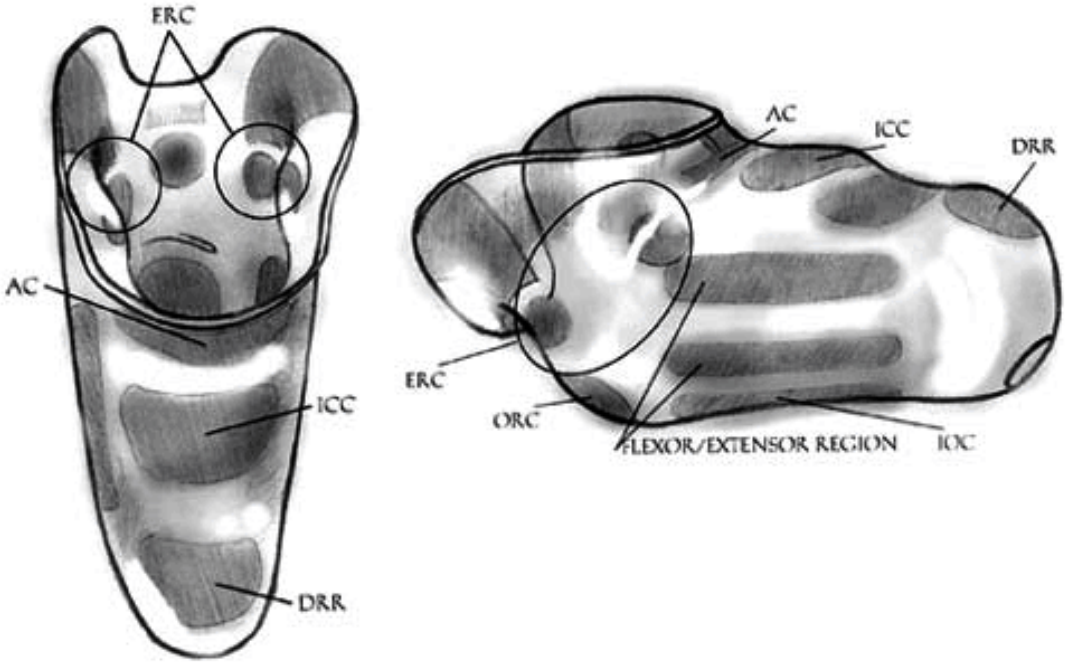

Figure 10. Line drawings identifying key areas of TRAC in frontal and sagittal views (interface only). ERC, epicondylar region contour; AC, antecubital channel; ICC, infracubital compartment; DRR, distal radial relief; ORC, olecranon region contour; IOC, infra-olecranon compression.

ANTECUBITAL CHANNEL

Create a channel parallel to the anterior trim line/cubital fold. The borders of the channel should correspond to the borders of the anterior trim line, as discussed above. The depth of the channel should approximate the deepest impression made by the index and middle fingers to identify the borders of the biceps tendon (Figure 11) .

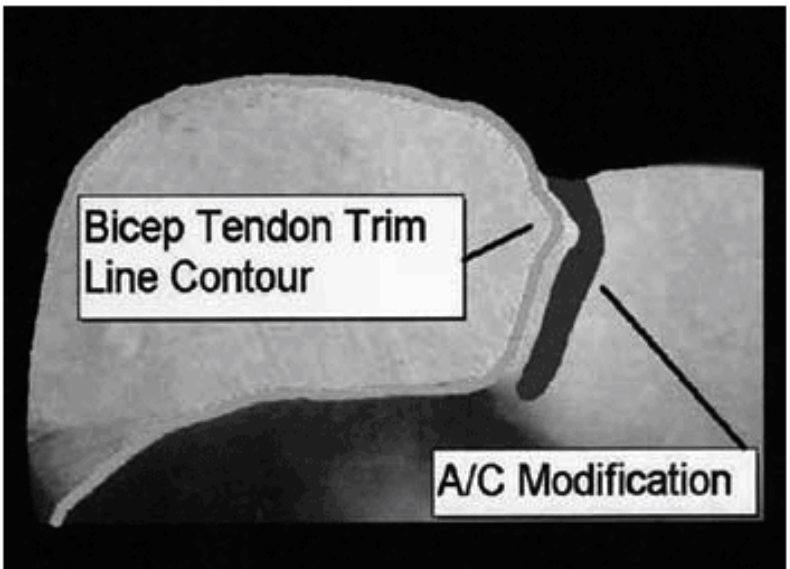

Figure 11. Antecubital channel (AC) model rectification.

INFRACUBITAL COMPARTMENT

The infracubital compartment (ICC) is a compartment for the musculature of the pronator teres, brachioradialis, flexor carpi radialis, and palmaris longus inferior to the antecubital channel (AC). This compartment is critical because it allows the musculature to contract freely while enhancing the range of motion. The contraction of this musculature within the ICC also creates additional suspension, preventing distal migration of the interface during loading. Other self-suspending designs lower the anterior trim line to accommodate muscle bunching at the cost of reduced stability and suspension.

This compartment is created by adding approximately 1 cm of material at its apex. Anatomically, the borders of this compartment (Figure 12) are superiorly at the inferior aspect of the AC, medially at the border of the flexor carpi radialis or palmaris longus, laterally at the brachioradialis, with inferior termination at a distance of two-thirds the length of the limb, as measured from the olecranon to the distal end. The medial, lateral, and inferior borders of this compartment require removal of material from the negative mold because they will provide an important load-bearing surface for the interface.

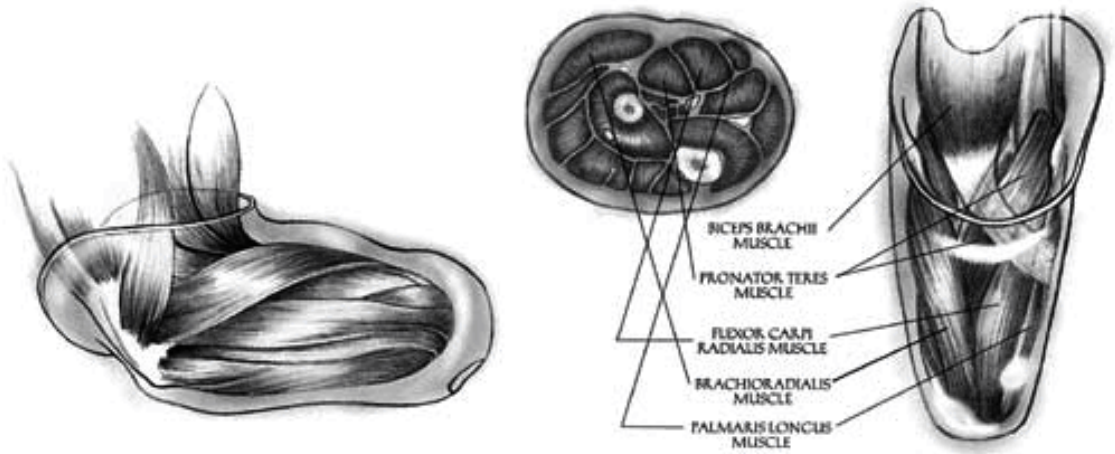

Figure 12. Line drawing of infracubital compartment (ICC) muscles (sagittal view and frontal view with cross section).

DISTAL RADIAL RELIEF

Three to eight millimeters of material should be added to the area identified during the impression technique representing the cut end of the radius. This rectification will be referred to as the distal radial relief. In rare situations, the patient may present with an ulna that is longer and more prominent than the radius. A similar buildup of material would be required to create a distal ulnar relief.

WRIST FLEXOR/EXTENSOR COMPARTMENTS

Removal of 5 to 8 mm of material on the m/l aspect of the model anterior and posterior to the wrist flexors and extensors provides additional stability to the interface while promoting muscle hypertrophy.

INFRA-OLECRANON COMPRESSION

Remove material from the inferior aspect of the olecranon to approximately 12 mm superior to the cut end of the ulna. The amount of material removed is equal to the amount of material added to the ICC. This ensures A/P stability, preventing radial translation during load bearing (refer to Figures 2-4).

OLECRANON REGION CONTOUR

Add 7 to 10 mm of material to the apex of the olecranon, concentrating more material on the superior aspect than the inferior aspect to create a relief for the olecranon during ranging of the elbow. Remove approximately 2 to 4 mm of material on the medial and lateral borders of the olecranon, being careful not to remove plaster on the epicondylar region previously marked. In addition, remove at least 5 to 8 mm of plaster beginning at the superior border of the olecranon and extending approximately 24 to 30 mm proximally to the posterior trim line, creating a reverse flare. The reverse flare prevents hyperextension and compresses on the triceps tendon, a load-tolerant area. This rectification reduces loading to the cut end of the radius. The contours of this area are critical to comfort, suspension, and ease of donning (Figure 13) .

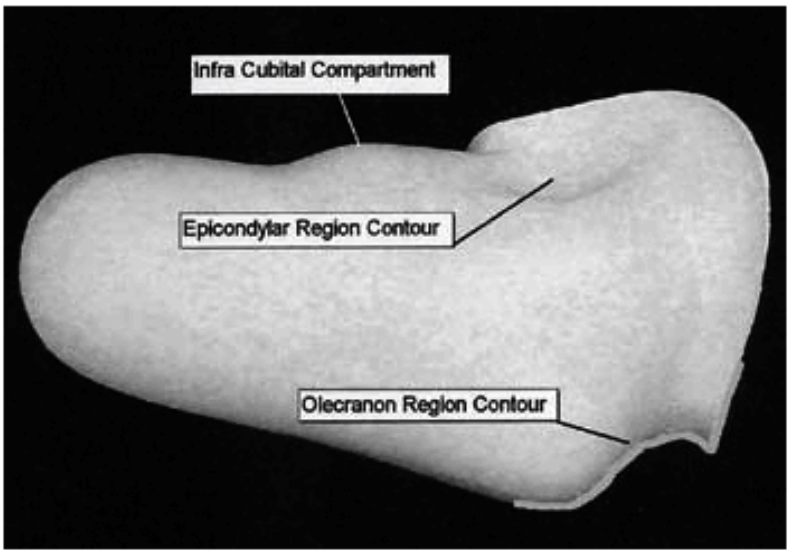

Figure 13. Infracubital compartment, olecranon region contour, and epicondylar region contour model rectification.

EPICONDYLAR REGION CONTOUR

Begin by adding 2 to 3 mm of material to the medial and lateral epicondyles as previously marked on the positive mold. Contour the area by removing plaster from the area anterior and inferior to the epicondyles, as indicated by the finger imprints during the impression to create a depression that flares smoothly toward the trim line (Figure 13) . This depression will enhance M/L stability and suspension by creating a skeletal lock. For individuals with prominent epicondyles, it may be necessary to create a channel in the medial and lateral stabilizers to facilitate donning and doffing. The authors' experience suggests this may be more effectively accomplished during the diagnostic phase than the model rectification.

DIAGNOSTIC ASSESSMENT

Once the model has been smoothed and blended accordingly, prepare a diagnostic socket formed from clear co-polyester material. The preferred thickness of the finished diagnostic interface is at least five millimeters. This thickness will allow for spot heating without deformation of other areas. In addition, blister or bubble thermoforming the positive model ensures that a seam will not interfere with regional thermo modifications.

For best results, the use of a donning sock is recommended (Figure 14) . There are several types of donning socks available; those that offer a low coefficient of friction are preferred. By pulling the patient into the TRAC interface, the soft tissue can be consistently placed within the interface, providing maximum padding about the skeletal substructure. Conversely, patients who push into the interface experience soft tissue tension about the skeletal substructure that can be particularly uncomfortable along the cut end of the radius and ulna because these areas often are sharp.

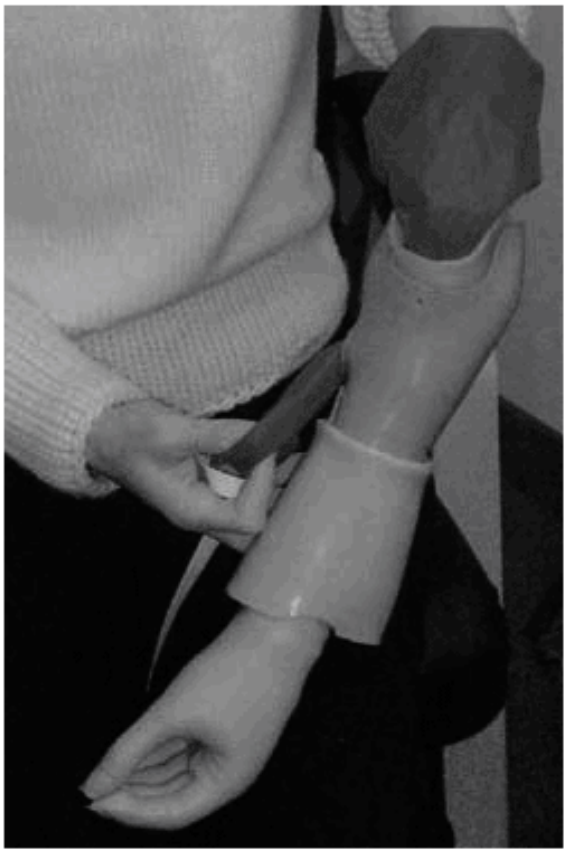

Figure 14. Use of a donning sock to don diagnostic interface.

While the diagnostic interface is being donned, carefully evaluate the medial and lateral epicondyles to ensure comfortable tracking of the epicondyles into the relief pockets. It is desirable for the epicondyles to "pop" into the epicondylar relief because this ensures maximum suspension. Careful monitoring of the patient's epicondylar region is important to prevent bruising because the material used in the diagnostic interface lacks the flexibility that will be incorporated into the definitive interface.

Once the patient is able to don the interface, evaluation of A/P stability should occur. When the elbow is positioned at 90╟, the interface should exhibit minimal pistoning in the A/P plane. Should pistoning or loss of suspension be present, often a more aggressive AC is necessary, which will effectively tighten the A/P compression of the interface. Elbow range of motion can be maximized by ensuring a high anterior trim line through the cubital fold area with sufficient biceps tendon relief and precise contouring of the supra-olecranon and supra-epicondylar areas. Additional elbow range of motion will be obtained in the definitive interface with the use of flexible material.

Once the proximal components of the interface have been adjusted appropriately, volumetric assessment of the interface distal to the cubital fold follows. Assessment of the muscle contouring incorporates the evaluation of the ICC, distal radial relief, and wrist extensor/flexor compartments. This additional contouring, not found in previous socket designs, helps stabilize the residual anatomy, as seen in the radiologic analysis. Appropriate volume and muscle contouring can be evaluated by observing tissue displacement while the patient resists force applied to the distal compartment of the interface in the A/P and M/L planes. Loading forces should not create excessive pressure to the tissue about the distal radial relief area. Effectively integrating the key elements of the TRAC design and obtaining an optimal fit often require several diagnostic interfaces.Once optimal comfort, range of motion, and stability have been achieved in the diagnostic interface, the focus shifts to prosthetic control. Although the TRAC interface design supports any control option, additional modification may be required when using myoelectric control because constant skin-to-electrode contact is necessary. To ensure proper skin-to-electrode contact, electromyographic (EMG) sites should be identified and marked on the residuum. After the diagnostic interface is donned, verify skin-to-interface contact at the sites marked on the residuum while ranging and loading the elbow. Electrodes can then be mounted in the diagnostic interface to confirm optimal contact and EMG signal. This verification process is particularly critical in some cases that involve severe trauma or congenital absence, in which the muscle(s) that have been identified as EMG sites are also used for elbow flexion or extension. If inadvertent opening or closing of the myoelectric terminal device occurs during ranging of the elbow, alternative EMG sites or conversion to a single EMG site control scheme may be required.

At this point, alignment of the prosthesis should take place. The TRAC interface design allows for greater elbow extension than do other designs. The extra range of motion gained in extension can be capitalized upon by preflexing the prosthetic forearm. Enhanced functional range of motion of the terminal device allows the patient to operate it closer to the head, facilitating feeding and grooming. The authors recommend attaching a diagnostic/temporary forearm, wrist, and terminal device to ensure optimal alignment.

The TRAC interface can now be integrated into the definitive prosthesis. Fabricate a thermoplastic flexible inner socket with a finished thickness of approximately 3 to 5 mm supported by a rigid outer frame (Table 3) that prevents loss of A/P and M/L compression while allowing flexibility about the trim lines. The combined characteristics of these materials will provide superior comfort, suspension, and range of motion. A pull hole/tube also should be incorporated into the inner socket and frame for the pull sock used in the donning of the definitive prosthesis. The pull hole typically is located in the distal medial compartment of the interface/frame combination.

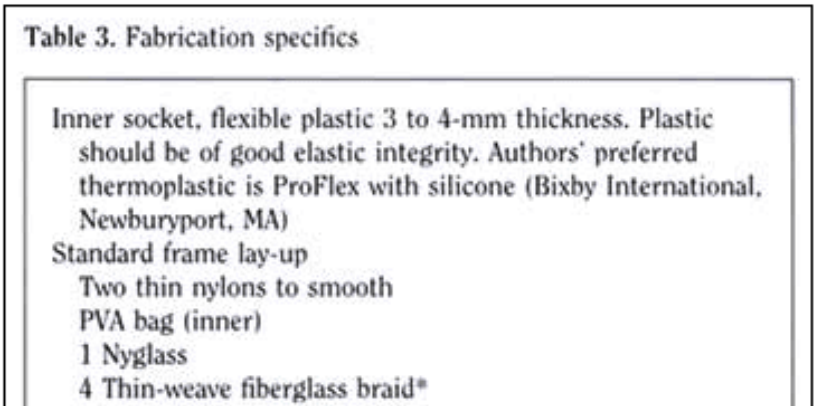

Table 3. Fabrication specifics

Inner socket, flexible plastic 3 to 4-mm thickness. Plastic should be of good elastic integrity. Authors' preferred thermoplastic is ProFlex with silicone (Bixby International, Newburyport, MA)

Standard frame lay-up
  Two thin nylons to smooth
  PVA bag (inner)
  1 Nyglass
  4 Thin-weave fiberglass braid*

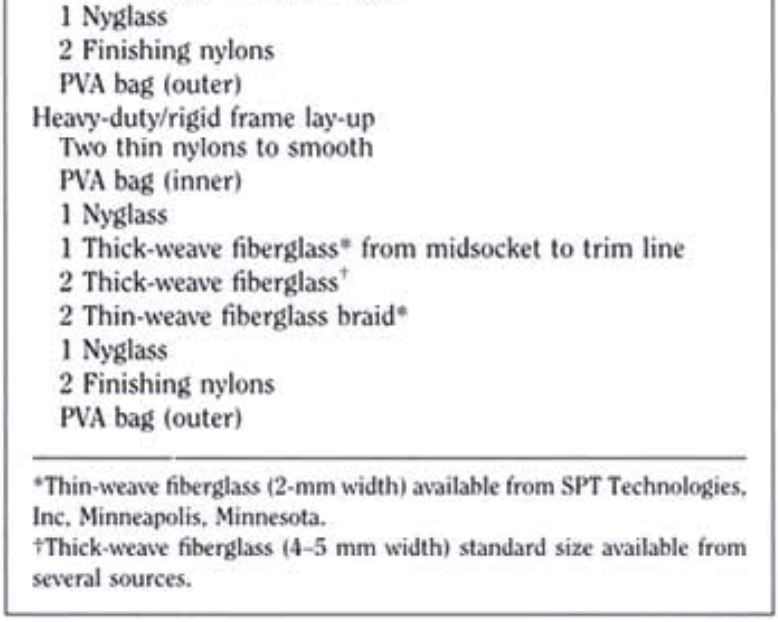

1 Nyglass
2 Finishing nylons
PVA bag (outer)
Heavy-duty/rigid frame lay-up
Two thin nylons to smooth
PVA bag (inner)
1 Nyglass
1 Thick-weave fiberglass* from midsocket to trim line
2 Thick-weave fiberglass†
2 Thin-weave fiberglass braid*
1 Nyglass
2 Finishing nylons
PVA bag (outer)

---

*Thin-weave fiberglass (2-mm width) available from SPT Technologies, Inc, Minneapolis, Minnesota.

†Thick-weave fiberglass (4–5 mm width) standard size available from several sources.

Table 3. Fabrication specifics

SPECIAL CONSIDERATIONS

Although the TRAC interface is applicable to any type of prosthetic option, including myoelectrically controlled, body-powered, and passive/cosmetic prostheses, special consideration should be given to certain residual limb presentations. The TRAC design relies on evenly dispersed A/P and M/L compression and contouring to achieve superior suspension and stability. However, unique residuum anatomy, such as missing or additional skeletal and muscular structures or excessive scar or graft tissue that often are associated with congenital deficiencies or severe trauma, may require a modified interface that concentrates additional compression and contouring in certain planes. For example, an individual with a congenital deficiency may lack sufficient radial head and epicondylar definition to provide suspension, thus necessitating more aggressive contouring of the AC, ICC, and supra-olecranon region. However, this resolution may compromise range of motion or stability.

Conversely, individuals who present longer residual limbs may require less aggressive contouring in the A/P plane for donning of the interface. To retain the suspension and stability characteristics of the TRAC design, more aggressive contouring in the M/L plane is needed. Care should be taken to prevent the anterior trim line of the interface from falling below the cubital fold because this will allow tissue bunching to limit elbow range of motion. It also should be noted that individuals with long residual limbs that retain supination and pronation capabilities should not be considered for the TRAC design because the skeletal lock inherent in the design prevents rotation of the radius and ulna.

Certain residual limbs exhibit extremely prominent epicondyles that may require channels in the supra-epicondylar region to facilitate donning. In some cases, a single channel is sufficient, and the patient can be instructed to don the interface by twisting the residual limb, seating one epicondyle while allowing the second epicondyle to enter through the channel.

For bilateral amputees, donning the TRAC interface requires the use of a longer lanyard attached to the pull sock that can be manipulated with the mouth, residuum, contralateral prosthesis or feet (Figure 15). Although this process is more challenging than the "push in" technique, the suspension, stability, and comfort afforded by "pull in" donning far outweighs the inconvenience. Contouring of the interface must be reduced if the patient is unable or unwilling to use a pull sock, which potentially affects range of motion and stability.



Ipsilateral knee and contralateral residual limb used to stabilize prosthesis during donning.



Figure 15. Bilateral amputee donning myoelectric prosthesis with the TRAC interface.

Some patients prefer an interface that does not encapsulate the olecranon because it allows for greater heat dissipation and enhanced proprioception.5 When this modification to the olecranon region (based on the three quarter socket design) is applied to the TRAC, more aggressive supra-olecranon contouring is needed to retain stability and suspension (Figure 16) . Additional advantages of this modification include ease of donning and greater range of motion. However, debris and perspiration are more likely to enter between the frame and the flexible inner socket, which may damage the delicate electronics that are located inside the prosthetic forearm. In addition, some patients prefer the olecranon to be protected by an encapsulated design.

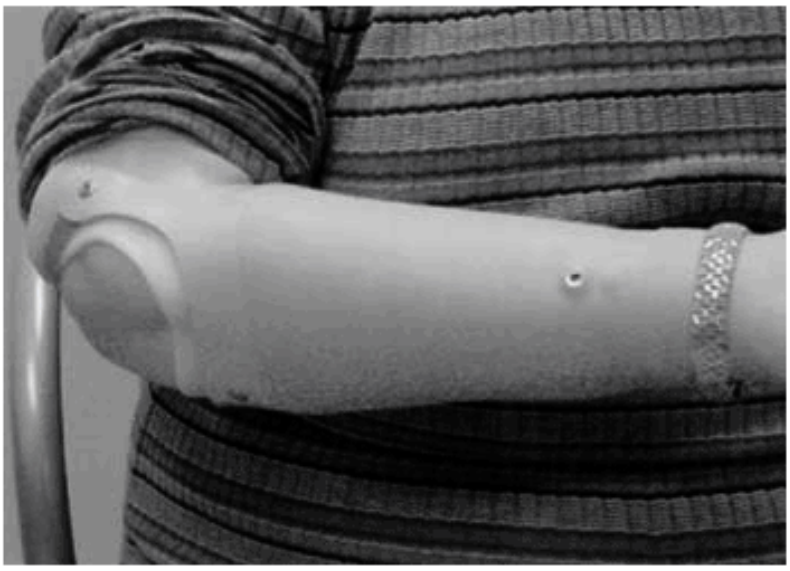

Figure 16. The TRAC interface with three-quarter modification.

CONCLUSION

Many patients initially were attracted to the myoelectric prosthesis because the transradial level self-suspending interface offered a functional alternative to the tight and restrictive harness inherent in a body-power controlled prosthesis. The dramatic improvement in comfort of the two most widely prescribed interface designs, the Muenster-type and the Northwestern Supracondylar Suspension Technique, motivated wearers to tolerate the experimental nature of early myoelectric components and facilitated their evolution. As more robust myoelectric components enabled patients to perform an ever-widening range of activities, the current interface designs themselves became a factor that limited the rehabilitation potential of patients. Functional gains and extended wearing times necessitated an interface that provided enhanced comfort, range of motion, stability, and suspension. Clinical experience suggests that the compartmental nature of the highly contoured and anatomically based TRAC interface shapes, stabilizes, and aligns the involved musculature more effectively than do the Muenster and Northwestern interface geometries. Radiologic analysis demonstrates the superior stability characteristics of the TRAC compared with previous interface designs. In addition, the TRAC allows greater elbow range of motion than does its predecessors, thus expanding the wearer's functional envelope.

The TRAC positively affects prosthetic control in several key areas. For body-powered prosthetic wearers, the TRAC decreases distal migration of the interface, improving the efficiency of excursion and terminal device control. It also increases the functional envelope for those using myoelectric control by maintaining skin-to-electrode contact throughout the range of motion. In summation, the geometry implemented in the TRAC design has a demonstrable positive effect on the stability, range of motion, and comfort of the amputee. Similarly, the indicators presented suggest that its aggressive muscle contouring has the potential to improve the electromyographic, hydrostatic, and cellular health of the involved residual limb and thus should be adequately weighted in the decision and rationale of all transradial fittings.

ACKNOWLEDGMENTS

The authors thank Michelle D. Miguelez for her invaluable contributions to this article. The authors also thank the following people for their assistance: Robert Carlisle, Scott Hoang, RTR-x-ray supervisor, and Brian Fisher, NCT, Irving Orthopedic; Charles Barnett, technical services coordinator, and Robert Scifres, prosthetic technician, AAD Texas; and David Burk, graphic artist.

JOHN M. MIGUELEZ, CP, FAAOP, is affiliated with Advanced Arm Dynamics, Inc., Rolling Hills Estates, California.

CHRISTOPHER LAKE, CPO, FAAOP, is affiliated with Advanced Arm Dynamics of Texas, LLC, Dallas, Texas.DAN CONYERS, CPO, is affiliated with Advanced Arm Dynamics, Inc., Beaverton, Oregon.

JOHN ZENIE, CPO, MBA, is affiliated with Advanced Arm Dynamics of New England, LLC, Guilford, Connecticut.Copyright ╘ 2003 American Academy of Orthotists and Prosthetists.Correspondence to: John M. Miguelez, CP, FAAOP, Advanced Arm Dynamics, Inc., 50-B Peninsula Center Drive, 172 Rolling Hills Estates, CA 90274-3506; e-mail: JMiguelez@aol.com.

References:

1. Billock JN. The Northwestern University supracondylar suspension technique for below-elbow amputations. Orthot Prosthet 1972;26:16-23.
2. Gorton A. The Muenster-type below-elbow prosthesis: a field study. Inter-Clinic Information Bulletin 1966;6:12-18.
3. Pellicore RJ. Experiences with the Hepp-Kuhn below elbow prosthesis: a preliminary report. Inter-Clinic Information Bulletin. 1964;3:1-7.
4. Hepp O, Kuhn GG. Upper extremity prostheses. Proceedings of the Second International Prosthetics Course, Copenhagen, Denmark, July 30-August 8, 1959.
5. Sauter WF, Naumann S, Milner M. A three-quarter type below elbow socket for myoelectric prostheses. Prosthet Orthot Int 1986;10:79-82.